

Clinical and Mycologic Characteristics of Emerging Mucormycosis Agent *Rhizopus homothallicus*

Shivaprakash M. Rudramurthy,¹ Shreya Singh,^{1,2} Rimjhim Kanaujia, Hansraj Chaudhary,³ Valliappan Muthu, Naresh Panda, Abhishek Pandey, Sheetal Thakur, Harsimran Kaur, Anup Ghosh, Ritesh Agarwal, Arunaloke Chakrabarti⁴



In support of improving patient care, this activity has been planned and implemented by Medscape, LLC and Emerging Infectious Diseases. Medscape, LLC is jointly accredited with commendation by the Accreditation Council for Continuing Medical Education (ACCME), the Accreditation Council for Pharmacy Education (ACPE), and the American Nurses Credentialing Center (ANCC), to provide continuing education for the healthcare team.

Medscape, LLC designates this Journal-based CME activity for a maximum of 1.00 **AMA PRA Category 1 Credit(s)**[™]. Physicians should claim only the credit commensurate with the extent of their participation in the activity.

Successful completion of this CME activity, which includes participation in the evaluation component, enables the participant to earn up to 1.0 MOC points in the American Board of Internal Medicine's (ABIM) Maintenance of Certification (MOC) program. Participants will earn MOC points equivalent to the amount of CME credits claimed for the activity. It is the CME activity provider's responsibility to submit participant completion information to ACCME for the purpose of granting ABIM MOC credit.

All other clinicians completing this activity will be issued a certificate of participation. To participate in this journal CME activity: (1) review the learning objectives and author disclosures; (2) study the education content; (3) take the post-test with a 75% minimum passing score and complete the evaluation at <http://www.medscape.org/journal/eid>; and (4) view/print certificate. For CME questions, see page XXX.

NOTE: It is Medscape's policy to avoid the use of Brand names in accredited activities. However, in an effort to be as clear as possible, the use of brand names should not be viewed as a promotion of any brand or as an endorsement by Medscape of specific products.

Release date: June 20, 2023; Expiration date: June 20, 2024

Learning Objectives

Upon completion of this activity, participants will be able to:

- Assess the proportion of *Rhizopus homothallicus* infection and clinical characteristics, including 30-day mortality in rhino-orbital mucormycosis from *R. homothallicus* vs *Rhizopus arrhizus*, of emerging *R. homothallicus* reported from a tertiary care center in India, based on a retrospective review of consecutive mucormycosis cases
- Evaluate the mycological characteristics, including antifungal susceptibility testing and amplified length polymorphism of emerging *Rhizopus homothallicus* reported from a tertiary care center in India, based on a retrospective review of consecutive mucormycosis cases
- Determine the clinical implications of the clinical and mycological characteristics of emerging *Rhizopus homothallicus* reported from a tertiary care center in India, based on a retrospective review of consecutive mucormycosis cases

CME Editor

Jude Rutledge, BA, Technical Writer/Editor, Emerging Infectious Diseases. *Disclosure: Jude Rutledge, BA, has no relevant financial relationships.*

CME Author

Laurie Barclay, MD, freelance writer and reviewer, Medscape, LLC. *Disclosure: Laurie Barclay, MD, has no relevant financial relationships.*

Authors

Shivaprakash M. Rudramurthy, MD, PhD; Shreya Singh, MD; Rimjhim Kanaujia, MD; Hansraj Chaudhary, MSc, PhD scholar; Valliappan Muthu, MD; Naresh Panda, MS; Abhishek Pandey, MSc; Sheetal Thakur, MSc, PhD scholar; Harsimran Kaur, MD; Anup Ghosh, PhD; Ritesh Agarwal, MD; and Arunaloke Chakrabarti, MD.

Author affiliation: Postgraduate Institute of Medical Education and Research, Chandigarh, India

DOI: <https://doi.org/10.3201/eid2907.221491>

¹These first authors contributed equally to this article.

²Current affiliation: Dr. B R Ambedkar State Institute of Medical Sciences, Mohali, India.

³Current affiliation: Indian Council of Medical Research, New Delhi, India.

⁴Current affiliation: Doodhadhari Burfani Hospital, Haridwar, India.

We retrospectively reviewed consecutive cases of mucormycosis reported from a tertiary-care center in India to determine the clinical and mycologic characteristics of emerging *Rhizopus homothallicus* fungus. The objectives were ascertaining the proportion of *R. homothallicus* infection and the 30-day mortality rate in rhino-orbital mucormycosis attributable to *R. homothallicus* compared with *R. arrhizus*. *R. homothallicus* accounted for 43 (6.8%) of the 631 cases of mucormycosis. *R. homothallicus* infection was independently associated with better survival (odds ratio [OR] 0.08 [95% CI 0.02–0.36]; $p = 0.001$) than for *R. arrhizus* infection (4/41 [9.8%] vs. 104/266 [39.1%]) after adjusting for age, intracranial involvement, and surgery. We also performed antifungal-susceptibility testing, which indicated a low range of MICs for *R. homothallicus* against the commonly used antifungals (amphotericin B [0.03–16], itraconazole [0.03–16], posaconazole [0.03–8], and isavuconazole [0.03–16]). 18S gene sequencing and amplified length polymorphism analysis revealed distinct clustering of *R. homothallicus*.

Mucormycosis is an angioinvasive disease caused by the saprophytic fungi of the order Mucorales. The estimated prevalence of mucormycosis is ≈ 70 times higher in India than elsewhere (1). *Rhizopus arrhizus* is the most common etiologic agent of mucormycosis in India and worldwide (2). Other reported Mucorales include *Apophysomyces variabilis*, *Cunninghamella* spp., *Lichtheimia* spp., *Mucor* spp., *Rhizomucor* spp., *Rhizopus microsporus*, *Rhizopus homothallicus*, *Saksenaia vasiformis*, *Syncephalastrum* spp., and *Thamostylum lucnowense* (3–7). *R. arrhizus* was the most common causative agent even during the recent outbreak of COVID-19-associated mucormycosis (CAM) in India (8). Although infection with *R. homothallicus* was also reported in a few patients (9), the importance of mucormycosis caused by *R. homothallicus* is unclear. We report the percentage of patients with mucormycosis caused by *R. homothallicus* at our center (Postgraduate Institute of Medical Education and Research [PGIMER], Chandigarh, India) and describe clinical features, mycologic characteristics, antifungal susceptibility, treatment, and mortality rates. We also assess whether the mortality rate from rhino-orbital mucormycosis (ROM) caused by *R. homothallicus* is different from that of *R. arrhizus* disease.

The primary objectives of this study were to assess the proportion of patients with mucormycosis caused by *R. homothallicus* and 30-day mortality rate from ROM caused by *R. homothallicus* and to determine whether the species of Mucorales (*R. homothallicus* vs. *R. arrhizus*) was an independent predictor of death from ROM. The secondary objectives were to compare the profile of patients infected with *R. homothallicus* versus *R. arrhizus* and to ascertain the mycologic characteristics of *R. homothallicus* isolates by conducting

antifungal-susceptibility testing (AFST) and amplified fragment length polymorphism (AFLP) analysis.

Methods

Study Design and Setting

We performed a retrospective study at PGIMER on a 10-month period (January–October 2021). Our center's institutional ethics committee approved the study protocol. We were granted a consent waiver because the study was a retrospective analysis of anonymized patient data. We report the study according to the Strengthening the Reporting of Observational Studies in Epidemiology statement (10). Data for a few participants published in this study have been reported in previous studies (11–13). We conducted the study in accordance with Declaration of Helsinki guidelines; the study was approved by the PGIMER Institutional Review Board (approval no. PGI/IEC/2021/001101) in August 2021.

Study Participants

We enrolled consecutive patients with ROM caused by *R. homothallicus* and *R. arrhizus*. The patients in whom mucormycosis caused by *R. homothallicus* and *R. arrhizus* was diagnosed were identified from our mycology laboratory records; we collected relevant clinical data from the patient records. We followed the study participants until discharge or 30 days after their mucormycosis was diagnosed. We sought any missing information for the study by contacting patients by telephone. We excluded patients for whom information was not adequate or not available. We obtained informed consent from all patients involved in the study.

Data Collection and Variables

For eligible patients with ROM, we retrieved data on age, sex, and risk factors for mucormycosis (e.g., diabetes mellitus, COVID-19 infection, organ transplantation, immunosuppressive therapy, hematologic malignancies). We defined diabetes mellitus as recently diagnosed if the disease was detected (hyperglycemia and glycated hemoglobin $>6.5\%$) during the current illness. We also retrieved clinical details, including signs and symptoms of ROM, treatment, and outcome of all patients (noted on follow up at 30 days after mucormycosis diagnosis, irrespective of discharge from hospital). All the study participants received the standard of care treatment in accordance with our institutional protocol.

Study Definitions

Mucormycosis was diagnosed in patients with compatible clinical and radiologic features and confirmed

by histopathologic or microbiologic methods, as previously described (8). We arbitrarily defined COVID-19-associated mucormycosis as mucormycosis diagnosed simultaneously with or within 3 months of virologically confirmed COVID-19 (14).

Phenotypic Identification of the Isolates

We inoculated tissue samples collected from patients on Sabouraud dextrose agar and dichloran rose bengal chloramphenicol (both from HiMedia, India) with benomyl. We isolated the Mucorales from the culture and confirmed them by demonstrating broad aseptate ribbon-shaped hyphae on direct microscopic examination of the samples. We performed phenotypic identification on the basis of the colony morphology (e.g., texture, growth rate, and color) and microscopic findings (i.e., lactophenol cotton blue mount prepared from slide culture) (15). We then summarized the distinctive features of *R. arrhizus* and *R. homothallicus* (Table 1; Figure 1).

Molecular Identification of the Isolates

We confirmed identification of all *R. homothallicus* isolates from ROM cases and 6 additional *R. homothallicus* isolates from pulmonary mucormycosis cases by using a molecular sequencing method. In addition,

we used sequences of 2 environmental isolates of *R. homothallicus* for comparison with clinical strains. We submitted to GenBank and included for phylogenetic analysis only isolates with good-quality sequences (Appendix Table 1, <https://wwwnc.cdc.gov/EID/article/29/7/22-1491-App1.pdf>). We included the DNA sequences of 1 isolate each of *R. microsporus* and *R. arrhizus* from our culture collection as controls. For DNA extraction, we used freshly grown sporulated culture suspended in 500 μ L of lysis buffer and incubated for 5 minutes at 56°C. We then extracted DNA by using the phenol–chloroform–isoamyl alcohol (25:24:1) method, as previously described (16). We used PCR-based amplification of the 18S, internal transcribed spacer, and 28S genes, followed by sequencing using previously published primers for molecular identification (17). Because we obtained mixed chromatograms in most isolates of *R. homothallicus* by sequencing the internal transcribed spacer and 28S regions, we used the sequences of 18S for phylogenetic analysis. We aligned all sequences of the study isolates and reference sequences of various *Rhizopus* species obtained from GenBank by using MEGA 7.0 (18). We studied the evolutionary relationship of isolates by constructing a phylogenetic tree by using neighbor-joining analysis in MEGA 7.0.

Table 1. Mycologic characteristics of *Rhizopus arrhizus* and *R. homothallicus* based on macroscopic and microscopic findings of tissue samples from patients enrolled in a 10-month retrospective study, Chandigarh, India, January–October 2021*

Characteristic	<i>R. homothallicus</i>	<i>R. arrhizus</i>
Macroscopic appearance		
Growth rate	Fast-growing colonies and sporulation relatively slower than <i>R. arrhizus</i>	Fast-growing colonies and sporulation relatively faster than <i>R. homothallicus</i>
Obverse surface growth	Cottony, white colonies that turn grayish to olive brown with a variegated appearance; because of the large-sized zygosporangia, brownish tufts can be seen unevenly distributed throughout the mycelial growth	Cottony, white colonies that turn gray with typical salt and pepper appearance
Reverse macroscopic findings	Reverse surface has no pigment	Reverse surface has no pigment
Microscopic findings		
Hyphae	Aseptate hyphae, less prominent rhizoids; smooth and thick-walled intercalary chlamydospore	Aseptate hyphae, well-developed nodal rhizoids with occasional intercalary chlamydospores
Sporangiophore	Erect, unbranched, or dichotomously branched (length 300–2000 μ m, width 5–30 μ m)	Single or tufts of mostly unbranched sporangiophores (length 1000–2000 μ m, width 7–18 μ m)
Sporangium	Sparsely noted in cultures; when present, appears spherical and greyish brown (20–140 μ m) with conspicuous dark apophysis and subspherical columella	Spherical sporangia (20–250 μ m) with short apophysis and spherical columella occupying 50% of sporangium
Sporangiospores	Spherical to broadly ellipsoidal (3–5 \times 4–8 μ m), hyaline, and thick-walled with less prominent striations	Lemon-shaped or subspherical to ellipsoidal (6–8 \times 4.5–5 μ m) with striations, rough surface
Zygosporangia	Homothallic†; abundant golden brown zygosporangia (60–100 μ m) with stellate spinous projections, attached to large globose suspensor cells that are unequal in size	Heterothallic zygosporangia not seen on primary culture ; red-brown spherical or laterally flattened (60–140 μ m) with flat projections; suspensors are unequal, spherical to conical

*Key features highlighted in bold.

†Differentiation from other homothallic *Rhizopus* species that produce abundant zygosporangia (e.g., *R. sexualis* and *R. azygosporus*) is done based on size of the suspensor cells of the zygosporangium and by molecular identification using the internal transcribed spacer and 28S sequences of rDNA.

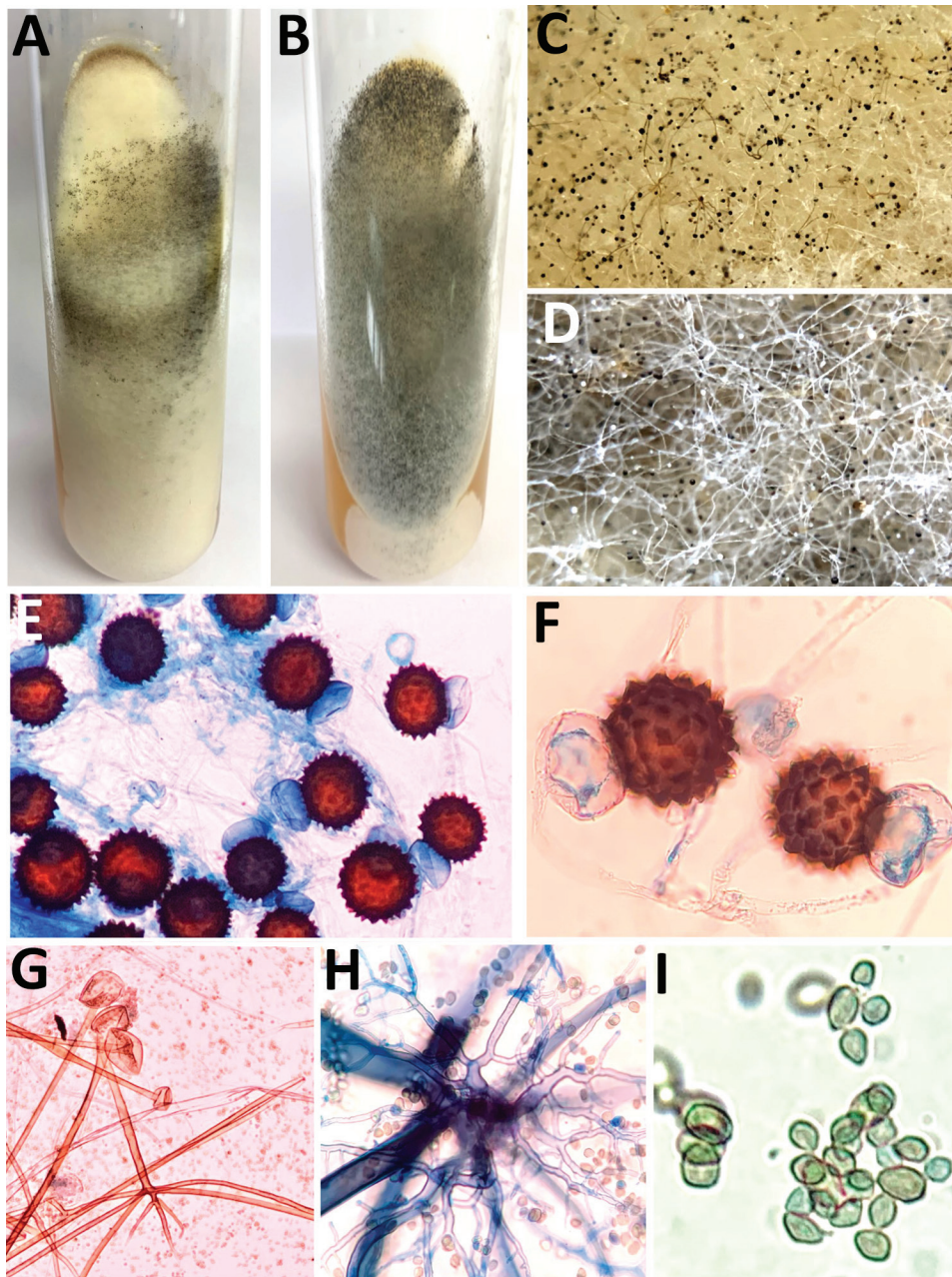


Figure 1. Macroscopic and microscopic characteristics of *Rhizopus arrhizus* and *R. homothallicus* isolated from tissue samples from patients enrolled in a 10-month retrospective study, Chandigarh, India, January–October 2021. A, B) Macroscopic appearance of colonies of *R. homothallicus* (A) and *R. arrhizus* (B) fungi. C, D) Macro lens image of the colonies showing dark-brown specks in *R. homothallicus* (C) and black and white dots (salt and pepper appearance) in *R. arrhizus* (D). E) Photomicrograph from a lactophenol cotton blue mount of *R. homothallicus* showing multiple reddish brown ornamented zygospores (original magnification $\times 400$). F) Magnified image of panel E showing unequal suspenser cells and zygospore with prominent spinous projections. G) *R. arrhizus* showing long, unbranched sporangiophore with nodal rhizoids (original magnification $\times 200$). H) Magnified image of extensively branched rhizoid seen in *R. arrhizus*. I) Magnified image of sporangiospores of *R. arrhizus*.

AFST

We performed AFST of the isolates for amphotericin B, itraconazole, posaconazole, isavuconazole, and terbinafine in accordance with Clinical and Laboratory Standards Institute (CLSI) standards (19). In brief, we diluted the drugs in the standard Roswell Park Memorial Institute 1640 medium and then dispensed 100 μL into each well of 96-well microdilution trays. We tested MICs in the range of 0.03–16 $\mu\text{g}/\text{mL}$. We prepared the inoculum by harvesting the zygospores in 0.85% normal saline and adjusted spore counts by using a spectrophotometer at an ab-

sorbance of 530 nm. On adjusting the optical density (OD) to limits of 0.15–0.17 ($0.4\text{--}5.0 \times 10^4$ zygospores/mL), we observed no growth on subsequent incubation; hence, we used a higher OD of 0.2–0.3 ($0.3\text{--}5.0 \times 10^6$ zygospores/mL, confirmed by counting on hemocytometer). We diluted the suspensions to 1:50 in Roswell Park Memorial Institute 1640 medium and incubated the microtiter plates at 35°C for 4–8 days until visible growth was observed in the growth control. We defined MIC endpoints as the lowest drug concentration that inhibited any recognizable growth. We used *Candida krusei* (ATCC 6258)

and *Aspergillus flavus* (ATCC 204304) as the quality-control strains.

Because of the absence or presence of fewer sporangiospores in *R. homothallicus*, performing AFST was challenging, and we modified the standard CLSI guidelines of AFST for this study. We used a higher OD with more inoculum containing both zygospores and hyphal fragments; performed intermittent vortexing of the inoculum for up to 45 minutes to ensure homogenous suspension (because zygospores tend to settle fast and are sometimes unevenly distributed between the wells); and conducted reading of AFST results up to 7 days (because zygospores take longer time to germinate or multiply compared with sporangiospores). The last step is in contrast to the standard protocol of reading the results at 24 hours for other medically important Mucorales, according to CLSI (19).

AFLP Analysis

We performed AFLP typing of *R. homothallicus* isolates as previously described (20). We used ≈ 50 ng of genomic DNA for the combined restriction-ligation procedure. We fragmented the DNA by using the 5 units each of restriction enzymes *EcoRI* and *HindIII* (New England Biolabs). For the preselective

amplification, we used 10 $\mu\text{mol/L}$ each of preselective primers of *EcoRI* primer (5'-GACTGCGTACCAATTC-3') and *HindIII* (5'-GACTGCGTACCA GCTT-3'). We used the 6-carboxyfluorescein (6-FAM) labeled primers for selective amplification. We used 10 $\mu\text{mol/L}$ each of *HindIII* primer (5'-ACTGCGTACAGCTTT-3') and *EcoRI* primer (5'-GACTGCGTACCAATTCAC-3') for selective amplification. We performed capillary electrophoresis to identify the restricted DNA fragments and reference marker (LIZ 500) in a genetic analyzer (3500 Genetic Analyzer 8 Capillary Array; Applied Biosystems). We imported the fingerprint data into BioNumerics 6.6 (Applied Maths) and converted curves into bands for analysis. We calculated the genetic diversity by using the Pearson correlation coefficient and clustered the isolates by using the unweighted pair group method with arithmetic mean. Although no definite cutoff for differentiating between strains exists, we used an arbitrary cutoff of <70% for genus differentiation and >70% for species differentiation. We defined clonal isolates when the similarity was in the range of 95%–99%.

Statistical Analysis

For statistical analysis, we used SPSS Statistics 22.0 (IBM) and GraphPad Prism 9.0 (GraphPad Soft-

Table 2. Comparison of mucormycosis caused by *Rhizopus homothallicus* versus *R. arrhizus* in patients enrolled in a 10-month retrospective study, Chandigarh, India, January–October 2021*

Parameter	<i>R. homothallicus</i> , n = 41	<i>R. arrhizus</i> , n = 266	p value
Mean age, y (\pm SD)	45.9 (\pm 12.8)	52.5 (\pm 12.7)	0.002
Sex			
M	23/41 (56.1)	182/266 (68.4)	0.15
F	18/41 (43.9)	84/266 (31.6)	
Risk factors			
CAM	23/41 (56.1)	256/266 (96.2)	0.0001
Duration after COVID-19, d (\pm SD)	6.13 (\pm 13.5)	11.9 (\pm 14.8)	0.07
Diabetes mellitus	39/41 (95.1)	223/238 (93.7)	0.72
Recently diagnosed diabetes mellitus	9/39 (23.1)	54/223 (24.2)	
Renal transplantation	0	1/238 (0.4)	1.00
Intracranial involvement	3/41 (7.3)	13/266 (4.9)	0.46
Clinical features			
Fever	4/41 (9.8)	3/55 (5.5)	0.42
Headache	4/41 (9.8)	10/55 (18.2)	0.38
Toothache	4/41 (9.8)	5/55 (9.1)	0.91
Eye swelling	27/41 (65.9)	27/55 (49.1)	0.10
Facial pain	11/41 (26.8)	22/55 (40)	0.18
Facial swelling	16/41 (39)	22/55 (40)	0.92
Proptosis	3/41 (7.3)	0	0.08
Visual disturbance	18/41 (43.9)	7/55 (12.7)	0.0005
Oral ulcer	3/41 (7.3)	10/55 (18.2)	0.12
Nasal crust	5/41 (12.2)	5/55 (9.1)	0.62
Palatal eschar	5/41 (12.2)	10/55 (18.2)	0.42
Management			
Amphotericin therapy	38/41 (92.7)	212/218 (97.2)	0.14
LAMB	36/38 (94.7)	196/212 (92.5)	
Conventional AMB	2/38 (5.3)	16/212 (7.5)	
Surgery	24/36 (66.7)	184/245 (75.1)	0.31
30-day mortality	4/41 (9.8)	104/266 (39.1)	0.0001

*Values are no. patients/no. with data available (%) except as indicated. CAM, COVID-19–associated mucormycosis; LAMB, liposomal amphotericin B; AMB, amphotericin.

Table 3. Binary logistic regression analysis demonstrating the factors associated with death among patients with rhino-orbital mucormycosis enrolled in a 10-month retrospective study, Chandigarh, India, January–October 2021*

Variable	Survivors	Nonsurvivors	Odds ratio (95% CI)	p value
Mean age, y (\pm SD)	55.8 (\pm 12.4)	49.4 (\pm 12.6)	1.06 (1.03–1.08)	0.0001
Male sex	124/199 (62.3)	81/108 (75)	1.38 (0.75–2.53)	0.31
Intracranial involvement	4/199 (2)	12/108 (11.1)	22.7 (4.03–128.1)	0.0001
Surgery for ROM	144/173 (83.2)	64/108 (59.3)	0.22 (0.11–0.43)	0.0001
<i>R. homothallicus</i> infection	37/199 (18.6)	4/108 (3.7)	0.08 (0.02–0.36)	0.001

*Values are no. patients/no. with data available (%) except as indicated. ROM, rhino-orbital mucormycosis.

ware). We present the descriptive data as mean \pm SD for continuous variables and frequencies with percentages for categorical variables. We compared differences between the 2 groups by using the χ^2 test and Fisher exact test for categorical variables, as appropriate, and used the Student *t*-test test to compare continuous data. We performed a binary logistic regression analysis of variables (age, sex, presence of brain involvement, combined medical-surgical therapy for ROM, and causative species [*R. homothallicus* vs. *R. arrhizus*]) that influenced the mortality rate for ROM and reported the adjusted odds ratio (aOR) and 95% CI. All the statistical tests were 2-sided, and we considered a *p* value <0.05 to be statistically significant.

Results

Of the 631 patients with culture-confirmed mucormycosis, 43 (6.8%) had infection attributable to *R. homothallicus*. We excluded 324 cases from the study (262 because of inadequate information [e.g., lost to follow up], 35 because of non-*R. arrhizus* and non-*R. homothallicus* mucormycosis, and 27 non-ROM cases). We analyzed 41 ROM cases caused by *R. homothallicus* and 266 consecutive ROM cases attributable to *R. arrhizus*.

The mean \pm SD age of the 307 patients with ROM was 51.6 years \pm 12.8 years, and most were men (205 [66.8%]). The mean age of patients with *R. arrhizus* infection was significantly higher than that for patients with ROM caused by *R. homothallicus*. Data on diabetes status were available for 279 patients; 93.9% had diabetes, and of those, 45 (16.1%) had diabetic ketoacidosis during the initial encounter. We observed no statistically significant difference between the risk factors proportion of patients with intracranial involvement or medical and surgical management in the 2 study groups (Table 2). The overall mortality rate was

35.2% (108/307) and was significantly higher among patients infected with *R. arrhizus* compared with *R. homothallicus* (39.1% vs. 9.8%; *p* = 0.0001). The mortality rate of patients with ROM caused by *R. homothallicus* was not significantly different between CAM and non-CAM subgroups (Appendix Table 2).

On multivariate analysis, infection with *R. homothallicus* and surgery for ROM were independently associated with lower odds of death. A higher age (odds ratio [OR] 1.01 [95% CI 1.03–1.08]) and the presence of brain involvement (OR 22.7 [95% CI 4.03–128.10]) were independently associated with higher mortality rates among ROM cases (Table 3).

We performed AFST for 34 *R. homothallicus* isolates. We calculated the geometric mean, range, and MICs at which 50% (MIC₅₀) and 90% (MIC₉₀) of isolates are inhibited for amphotericin B, itraconazole, posaconazole, isavuconazole, and terbinafine (Table 4).

The phylogram constructed using 18S sequences (40 clinical and 2 environmental isolates of *R. homothallicus* and 1 each of *R. arrhizus* and *R. microsporus*) (Figure 2; Appendix Table 1) and the AFLP results (Appendix Figure) both revealed distinct clustering of *R. homothallicus* from the other tested species. We observed no prominent clades among isolates of *R. homothallicus* from patients with CAM versus non-CAM.

Discussion

We report a 6.8% prevalence of *R. homothallicus* infection among culture-confirmed mucormycosis cases. The mortality rate for ROM caused by *R. homothallicus* was significantly less than that for *R. arrhizus* (9.8% vs. 39.1%) after adjusting for age, sex, intracranial extension of the disease, and surgery for mucormycosis in the binary logistic regression model. The AFST data indicated good susceptibility to the common antifungal drugs and the newer agent isavuconazole.

Table 4. Distribution of MICs of 34 *Rhizopus homothallicus* isolates from patients enrolled in a 10-month retrospective study, Chandigarh, India, January–October 2021*

Antifungal agent	Geometric mean (range), mg/L	MIC ₅₀ , mg/L	MIC ₉₀ , mg/L
Amphotericin B	0.75 (0.03–16)	2	4
Itraconazole	0.51 (0.03–16)	0.5	8
Posaconazole	0.24 (0.03–8)	0.12	2
Isavuconazole	0.32 (0.03–16)	0.25	2
Terbinafine	0.34 (0.03–16)	0.25	4

*MIC₅₀, MIC at which 50% of isolates are inhibited; MIC₉₀, MIC at which 90% of isolates are inhibited.




Figure 2. Evolutionary relationships of 40 *Rhizopus homothallicus* isolates from patients in a 10-month study, Chandigarh, India, January–October 2021, and 2 environmental isolates. January–October 2021. GenBank accession numbers of 41 clinical and 1 environmental–MTCC 602 isolate of *R. homothallicus* from India are shown. Tree generated using neighbor-joining algorithm with 1,000 bootstrap replicates.

The 18S gene sequencing and AFLP revealed distinct clustering of *R. homothallicus* from the common species implicated in ROM.

Human infection with *R. homothallicus* was first reported from North India (4) in a case of pulmonary mucormycosis and was followed by a few more reports (5,21). In 2 prospective multicenter studies from India, *R. homothallicus* accounted for 2.5% (6/239) (22) and 7.6% (22/290) (23) of the cases where the causative organism could be identified. Despite a higher prevalence of mucormycosis cases (associated with the CAM outbreak) in our study, the prevalence of *R. homothallicus* mucormycosis (6.8%) was similar that in the previous reports.

R. homothallicus, a homothallic fungus, produces more heavy sexual spores than asexual spores (sporangiospores) and undergoes less dispersion in the air. The relative amount of sporangiospores is considerably lower in *R. homothallicus* than in the heterothallic *Rhizopus* species (24). Consequently, the chances of acquiring infection with *R. homothallicus* are expected to be low. Thus, *R. homothallicus* infections probably indicate the presence of some unidentified environmental niche where this agent can produce asexual spores abundantly and disperse them in the air. Recent studies have shown *R. homothallicus* in the hospital air and air samples obtained from the residence of patients with mucormycosis (25,26).

The mortality rate for mucormycosis may vary with the causative species. For instance, 2 systematic reviews have shown higher mortality rates for infections with *Cunninghamella* spp. than those with *R. arrhizus* (2,27). We observed a significantly better survival rate with *R. homothallicus* infection compared with *R. arrhizus*. A substantially higher proportion of patients with *R. homothallicus* infection had visual disturbance (44% vs. 13% for *R. arrhizus*), and this difference could have led to earlier detection. The duration of symptoms in CAM patients with mucormycosis caused by *R. homothallicus* and *R. arrhizus* was also different, although not significantly (6 vs. 12 days; $p = 0.07$). The timely initiation of antifungal therapy, intracranial spread of disease, and surgery for mucormycosis are important factors determining the outcome of mucormycosis (28,29). We conducted a preliminary growth curve analysis at 25°C, 37°C, and 40°C (data not shown) to determine whether the 2 species had a difference in growth rate. We observed an overall faster time to log phase at all temperatures for *R. arrhizus* compared with *R. homothallicus* (6 h vs. 27 h at 25°C, 5 h vs. 32 h at 37°C, and 6 h vs. 25 h at 40°C). However,

further in vivo studies are required to identify the different pathogenic potentials of these 2 Mucorales species.

The first limitation of our study was that it was retrospective and conducted at a single center, limiting generalizability. We do not have information on all patients with ROM caused by *R. arrhizus*, and the proportion of patients with CAM was much higher in the *R. arrhizus* group than in the *R. homothallicus* group. However, data from our center and another large multicenter study from India showed similar mortality rates for ROM with or without COVID-19 co-infection (8,11). Because our study focused exclusively on ROM cases, future studies should explore pulmonary or other sites of involvement, which are inherently associated with higher mortality rates (30). Although we noted a lower mortality rate from *R. homothallicus* infection on multivariate analysis, we cannot exclude residual confounding factors that could have resulted in improved survival with *R. homothallicus* infection. Also, we do not have a detailed evaluation of risk factors or genetic analysis to ascertain whether specific factors predispose persons to infection with *R. homothallicus*. Although the AFLP method is known for poor reproducibility, the results may be within an acceptable range when the test is repeated with the same batch of reagents, as we observed with our *R. homothallicus* isolates. Moreover, modification of the AFST protocol makes the results difficult to interpret and compare with published data.

In conclusion, our results show that *R. homothallicus* is an important agent of mucormycosis with epidemiologic and clinical significance. *R. homothallicus* may be less virulent or manifest earlier than *R. arrhizus*, thus resulting in better survival. Identifying *R. homothallicus* based on macroscopic and microscopic appearance is not difficult and should be emphasized. Most *R. homothallicus* isolates are uniformly susceptible to the commonly used antifungal agents to manage mucormycosis.

The Indian Council of Medical Research partially funded this work (grant no. ref no. AMR/149/2018-ECD-II).

Author contributions: conceptualization (S.M.R. and A.C.); methodology (S.S., R.K., N.P., H.C., A.P., and S.T.); formal analysis (S.S. and R.K.); investigations (H.C., A.P., R.K., and H.K.); resources (S.M.R. and A.C.); data curation (R.K., S.T., N.P., and V.M.); data interpretation (A.C., S.M.R., S.S., and V.M.); writing original draft (S.S.); writing review and editing (A.C., S.M.R., R.K., H.K., A.G., V.M., and R.A.); visualization (S.S.); and project administration (A.C.).

About the Author

Dr. Rudramurthy is professor and heads the Mycology Division of the Medical Microbiology Department at the Postgraduate Institute of Medical Education and Research in Chandigarh, India. His primary research interests include epidemiology, antifungal resistance, and molecular diagnosis of fungal infections. Dr. Singh is an assistant professor at the Dr. B R Ambedkar State Institute of Medical Sciences in Mohali, India. Her primary research interests include medial mycology, fungal diagnostics, and invasive fungal diseases.

References

- Prakash H, Chakrabarti A. Epidemiology of mucormycosis in India. *Microorganisms*. 2021;9:523. <https://doi.org/10.3390/microorganisms9030523>
- Jeong W, Keighley C, Wolfe R, Lee WL, Slavin MA, Kong DCM, et al. The epidemiology and clinical manifestations of mucormycosis: a systematic review and meta-analysis of case reports. *Clin Microbiol Infect*. 2019;25:26-34. <https://doi.org/10.1016/j.cmi.2018.07.011>
- Singh S, Pal N, Chander J, Sardana R, Mahajan B, Joseph N, et al. Mucormycosis caused by *Syncephalastrum* spp.: clinical profile, molecular characterization, antifungal susceptibility and review of literature. *Clin Infect Pract*. 2021;11:100074. <https://doi.org/10.1016/j.clinpr.2021.100074>
- Chakrabarti A, Marak RS, Shivaprakash MR, Gupta S, Garg R, Sakhuja V, et al. Cavitory pulmonary zygomycosis caused by *Rhizopus homothallicus*. *J Clin Microbiol*. 2010;48:1965-9. <https://doi.org/10.1128/JCM.01272-09>
- Kokkayil P, Pandey M, Agarwal R, Kale P, Singh G, Xess I. *Rhizopus homothallicus* causing invasive infections: series of three cases from a single centre in North India. *Mycopathologia*. 2017;182:921-6. <https://doi.org/10.1007/s11046-017-0153-5>
- Chakrabarti A, Ghosh A, Prasad GS, David JK, Gupta S, Das A, et al. *Apophysomyces elegans*: an emerging zygomycete in India. *J Clin Microbiol*. 2003;41:783-8. <https://doi.org/10.1128/JCM.41.2.783-788.2003>
- Chakrabarti A, Shivaprakash MR, Curfs-Breuker I, Baghela A, Klaassen CH, Meis JF. *Apophysomyces elegans*: epidemiology, amplified fragment length polymorphism typing, and in vitro antifungal susceptibility pattern. *J Clin Microbiol*. 2010;48:4580-5. <https://doi.org/10.1128/JCM.01420-10>
- Patel A, Agarwal R, Rudramurthy SM, Shevkani M, Xess I, Sharma R, et al. MucoCovi Network3. Multicenter epidemiologic study of coronavirus disease-associated mucormycosis, India. *Emerg Infect Dis*. 2021;27:2349-59. <https://doi.org/10.3201/eid2709.210934>
- Kaur H, Kanaujia R, Rudramurthy SM. *Rhizopus homothallicus*: an emerging pathogen in era of COVID-19 associated mucormycosis. *Indian J Med Microbiol*. 2021;39:473-4. <https://doi.org/10.1016/j.ijmmb.2021.06.013>
- Vandenbroucke JP, von Elm E, Altman DG, Gøtzsche PC, Mulrow CD, Pocock SJ, et al. STROBE Initiative. Strengthening the Reporting of Observational Studies in Epidemiology (STROBE): explanation and elaboration. *Int J Surg*. 2014;12:1500-24. <https://doi.org/10.1016/j.ijsu.2014.07.014>
- Muraleedharan M, Panda NK, Angrish P, Arora K, Patro SK, Bansal S, et al. As the virus sowed, the fungus reaped! A comparative analysis of the clinico-epidemiological characteristics of rhino-orbital mucormycosis before and during COVID-19 pandemic. *Mycoses*. 2022;65:567-76. <https://doi.org/10.1111/myc.13437>
- Muthu V, Dhaliwal M, Sharma A, Nair D, Kumar HM, Rudramurthy SM, et al. Serum glucose-regulated protein 78 (GRP78) levels in COVID-19-associated mucormycosis: results of a case-control study. *Mycopathologia*. 2022;187:355-62. <https://doi.org/10.1007/s11046-022-00645-6>
- Kumar H M, Sharma P, Rudramurthy SM, Sehgal IS, Prasad KT, Pannu AK, et al. Serum iron indices in COVID-19-associated mucormycosis: a case-control study. *Mycoses*. 2022;65:120-7. <https://doi.org/10.1111/myc.13391>
- Muthu V, Agarwal R, Patel A, Kathirvel S, Abraham OC, Aggarwal AN, et al. Definition, diagnosis, and management of COVID-19-associated pulmonary mucormycosis: Delphi consensus statement from the Fungal Infection Study Forum and Academy of Pulmonary Sciences, India. *Lancet Infect Dis*. 2022;22:e240-53. [https://doi.org/10.1016/S1473-3099\(22\)00124-4](https://doi.org/10.1016/S1473-3099(22)00124-4)
- de Hoog GS, Guarro J, Gene J, Ahmed SA, Al-Hatmi AMS, Figueras MJ, et al. Atlas of clinical fungi. 4th edition. Hilversum: Foundation Atlas of Fungi; 2020
- Shivaprakash MR, Appannanavar SB, Dhaliwal M, Gupta A, Gupta S, Gupta A, et al. *Colletotrichum truncatum*: an unusual pathogen causing mycotic keratitis and endophthalmitis. *J Clin Microbiol*. 2011;49:2894-8. <https://doi.org/10.1128/JCM.00151-11>
- White TJ, Bruns S, Lee S, Taylor J. Amplification and direct sequencing of fungal ribosomal RNA genes for phylogenetics. In: Innis MA, Gelfand DH, Sninsky JJ, White TJ, editors. PCR protocols: a guide to methods and applications. London: Academic Press; 1990. p. 315-22.
- Kumar S, Stecher G, Tamura K. MEGA7: Molecular Evolutionary Genetics Analysis version 7.0 for bigger datasets. *Mol Biol Evol*. 2016;33:1870-4. <https://doi.org/10.1093/molbev/msw054>
- Clinical and Laboratory Standards Institute. Reference method for broth dilution antifungal susceptibility testing of filamentous fungi. 3rd edition. 2017 Nov 30 [cited 2018 Aug 2]. <https://clsi.org/standards/products/microbiology/documents/m38>
- Prakash H, Ghosh AK, Rudramurthy SM, Paul RA, Gupta S, Negi V, et al. The environmental source of emerging *Apophysomyces variabilis* infection in India. *Med Mycol*. 2016;54:567-75. <https://doi.org/10.1093/mmy/myw014>
- Compain F, Ait-Ammar N, Botterel F, Gibault L, Le Pimpec Barthes F, Dannaoui E. Fatal pulmonary mucormycosis due to *Rhizopus homothallicus*. *Mycopathologia*. 2017;182:907-13. <https://doi.org/10.1007/s11046-017-0151-7>
- Prakash H, Ghosh AK, Rudramurthy SM, Singh P, Xess I, Savio J, et al. A prospective multicenter study on mucormycosis in India: epidemiology, diagnosis, and treatment. *Med Mycol*. 2019;57:395-402. <https://doi.org/10.1093/mmy/myy060>
- Patel A, Kaur H, Xess I, Michael JS, Savio J, Rudramurthy S, et al. A multicentre observational study on the epidemiology, risk factors, management and outcomes of mucormycosis in India. *Clin Microbiol Infect*. 2020;26:944.e9-15.
- Kaerger K, Schwartze VU, Dolatabadi S, Nyilasi I, Kovács SA, Binder U, et al. Adaptation to thermotolerance in *Rhizopus* coincides with virulence as revealed by avian and invertebrate infection models, phylogeny, physiological and metabolic flexibility. *Virulence*. 2015;6:395-403. <https://doi.org/10.1080/21505594.2015.1029219>

25. Biswal M, Gupta P, Kanaujia R, Kaur K, Kaur H, Vyas A, et al. Evaluation of hospital environment for presence of Mucorales during COVID-19-associated mucormycosis outbreak in India: a multi-centre study. *J Hosp Infect.* 2022;122:173–9. <https://doi.org/10.1016/j.jhin.2022.01.016>
26. Ghosh AK, Singh R, Reddy S, Singh S, Rudramurthy SM, Kaur H, et al. Evaluation of environmental Mucorales contamination in and around the residence of COVID-19-associated mucormycosis patients. *Front Cell Infect Microbiol.* 2022;12:953750. <https://doi.org/10.3389/fcimb.2022.953750>
27. Roden MM, Zaoutis TE, Buchanan WL, Knudsen TA, Sarkisova TA, Schaufele RL, et al. Epidemiology and outcome of zygomycosis: a review of 929 reported cases. *Clin Infect Dis.* 2005;41:634–53. <https://doi.org/10.1086/432579>
28. Cornely OA, Alastruey-Izquierdo A, Arenz D, Chen SCA, Dannaoui E, Hochhegger B, et al.; Mucormycosis ECMM MSG Global Guideline Writing Group. Global guideline for the diagnosis and management of mucormycosis: an initiative of the European Confederation of Medical Mycology in cooperation with the Mycoses Study Group Education and Research Consortium. *Lancet Infect Dis.* 2019;19:e405–21. [https://doi.org/10.1016/S1473-3099\(19\)30312-3](https://doi.org/10.1016/S1473-3099(19)30312-3)
29. Muthu V, Rudramurthy SM, Chakrabarti A, Agarwal R. Epidemiology and pathophysiology of COVID-19-associated mucormycosis: India versus the rest of the world. *Mycopathologia.* 2021;186:739–54. <https://doi.org/10.1007/s11046-021-00584-8>
30. Muthu V, Agarwal R, Dhooria S, Sehgal IS, Prasad KT, Aggarwal AN, et al. Has the mortality from pulmonary mucormycosis changed over time? A systematic review and meta-analysis. *Clin Microbiol Infect.* 2021;27:538–49. <https://doi.org/10.1016/j.cmi.2020.12.035>

Address for correspondence: Arunaloke Chakrabarti, Director Office, Doodhadhari Burfani Hospital, Haridwar, Uttarakhand, India; email: arunaloke@hotmail.com



@CDC_EIDJournal

Want to stay updated on the latest news in *Emerging Infectious Diseases*? Let us connect you to the world of global health. Discover groundbreaking research studies, pictures, podcasts, and more by following us on Twitter at @CDC_EIDJournal.

Clinical and Mycologic Characteristics of Emerging Mucormycosis Agent *Rhizopus homothallicus*

Appendix

Appendix Table 1. Accession numbers of 18 S ribosomal RNA sequences of the isolates used in the present study.

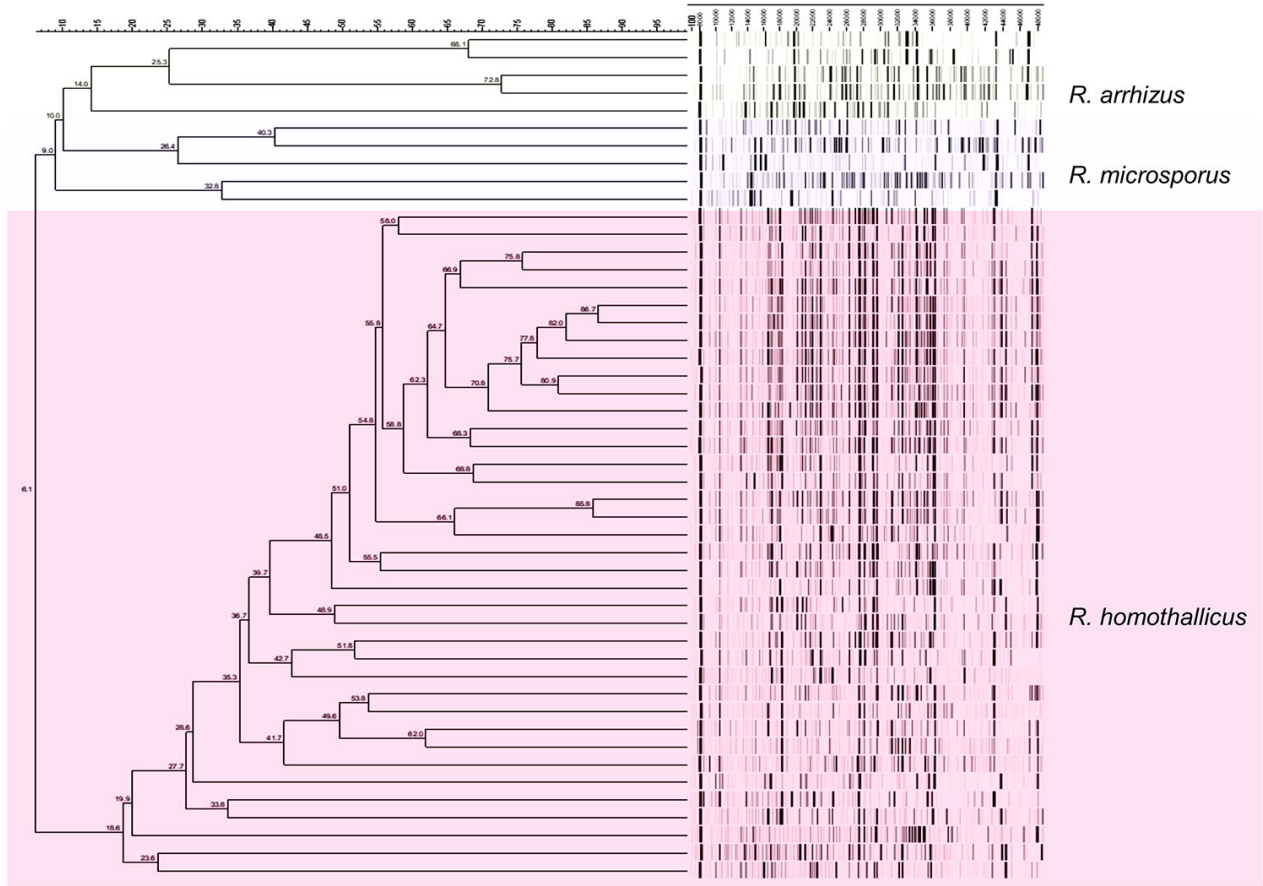
S no.	NCCPF no.	NCBI accession no.	Species	Site of isolation
1	710378	OM977050	<i>R. homothallicus</i>	Rhino-orbital mucormycosis
2	710380	OM977051	<i>R. homothallicus</i>	Rhino-orbital mucormycosis
3	710810	OM977052	<i>R. homothallicus</i>	Rhino-orbital mucormycosis
4	710811	OM977053	<i>R. homothallicus</i>	Rhino-orbital mucormycosis
5	710812	OM977054	<i>R. homothallicus</i>	Rhino-orbital mucormycosis
6	710813	OM977055	<i>R. homothallicus</i>	Rhino-orbital mucormycosis
7	710814	OM977056	<i>R. homothallicus</i>	Rhino-orbital mucormycosis
8	710817	OM977057	<i>R. homothallicus</i>	Rhino-orbital mucormycosis
9	710823	OM977058	<i>R. microsporus</i>	Rhino-orbital mucormycosis
10	710818	OM977059	<i>R. homothallicus</i>	Environmental
11	710555	OM977060	<i>R. homothallicus</i>	Rhino-orbital mucormycosis
12	710600	OM977061	<i>R. homothallicus</i>	Rhino-orbital mucormycosis
13	710668	OM977062	<i>R. homothallicus</i>	Rhino-orbital mucormycosis
14	710799	OM977063	<i>R. homothallicus</i>	Rhino-orbital mucormycosis
15	710800	OM977064	<i>R. homothallicus</i>	Rhino-orbital mucormycosis
16	710801	OM977065	<i>R. homothallicus</i>	Rhino-orbital mucormycosis
17	710678	OM977066	<i>R. homothallicus</i>	Rhino-orbital mucormycosis
18	710802	OM977067	<i>R. homothallicus</i>	Rhino-orbital mucormycosis
19	710686	OM977068	<i>R. homothallicus</i>	Rhino-orbital mucormycosis
20	710734	OM977069	<i>R. arrhizus</i>	Rhino-orbital mucormycosis
21	710732	OM977070	<i>R. homothallicus</i>	Rhino-orbital mucormycosis
22	710804	OM977071	<i>R. homothallicus</i>	Rhino-orbital mucormycosis
23	710815	OM977072	<i>R. homothallicus</i>	Rhino-orbital mucormycosis
24	710805	OM977073	<i>R. homothallicus</i>	Rhino-orbital mucormycosis
25	710871	OM977074	<i>R. homothallicus</i>	Rhino-orbital mucormycosis
26	710760	OM977075	<i>R. homothallicus</i>	Rhino-orbital mucormycosis
27	710869	OM977076	<i>R. homothallicus</i>	Rhino-orbital mucormycosis
28	710870	OM977077	<i>R. homothallicus</i>	Rhino-orbital mucormycosis
29	710873	OM977078	<i>R. homothallicus</i>	Rhino-orbital mucormycosis
30	710806	OM977079	<i>R. homothallicus</i>	Rhino-orbital mucormycosis
31	710917	OM977080	<i>R. homothallicus</i>	Rhino-orbital mucormycosis
32	710807	OM977081	<i>R. homothallicus</i>	Pulmonary mucormycosis
33	710905	OM977082	<i>R. homothallicus</i>	Pulmonary mucormycosis
34	710885	OM977083	<i>R. homothallicus</i>	Pulmonary mucormycosis
35	710808	OM977084	<i>R. homothallicus</i>	Pulmonary mucormycosis
36	710809	OM977085	<i>R. homothallicus</i>	Pulmonary mucormycosis
37	710816	OM977086	<i>R. homothallicus</i>	Rhino-orbital mucormycosis
38	710715	OM977087	<i>R. homothallicus</i>	Rhino-orbital mucormycosis
39	710766	OM977088	<i>R. homothallicus</i>	Rhino-orbital mucormycosis
40	710762	OM977089	<i>R. homothallicus</i>	Rhino-orbital mucormycosis
41	710890	OM977090	<i>R. homothallicus</i>	Rhino-orbital mucormycosis
42	710881	OM977091	<i>R. homothallicus</i>	Rhino-orbital mucormycosis
43	710872	OM977092	<i>R. homothallicus</i>	Pulmonary mucormycosis

NCCPF National Culture Collection of Pathogenic Fungi, NCBI National Center for Biotechnology Information.

Appendix Table 2. Comparison of various clinical and demographic parameters between patients with CAM and Non-CAM due to *R. homothallicus*.

Parameter	<i>R. homothallicus</i> CAM	<i>R. homothallicus</i> Non-CAM	P value
	n-23(%)	n-18 (%)	
Age (years)	46.6 ± 12.7	44.8 ± 13.1	0.667
Gender (F)	12 (52.2)	6 (33.3)	0.343
DM	21 (91.3)	18 (100)	0.495
UDM	20 (95.2)	10 (55.6)	0.006
Recently diagnosed diabetes	8 (38.1)	1 (5.6%)	0.023
Hypertension	7 (30.4)	1 (5.6)	0.059
Steroid	6 (26.1)	0 (0)	0.027
Clinical features			
Duration of symptom at presentation (days)	4.09 ± 1.4	7.9 ± 8.5	0.040
Fever	0	4 (22.2)	0.030
Headache	2 (8.7)	2 (11.1)	1.000
Toothache	4 (17.4)	0	0.118
Eye swelling	20 (87)	7 (38.9)	0.002
Facial pain	5 (21.7)	6 (33.3)	0.489
Facial swelling	10 (43.5)	6 (33.3)	0.540
Proptosis	0	3 (16.7)	0.077
Visual disturbance	8 (34.8)	10 (50)	0.219
Oral ulcer	3 (13)	0	0.243
Nasal crust	3 (13)	2 (11.1)	1.000
Palatal eschar	2 (8.7)	3 (16.7)	0.638
Treatment/Outcome			
30 d mortality	1 (4.3)	3 (16.7)	0.303
Antifungal	22 (95.7)	16 (88.9)	0.573
LAMB	22 (95.7)	14 (77.8)	0.150

CAM: COVID-19 associated mucormycosis; DM- Diabetes mellitus; UDM – uncontrolled diabetes mellitus; LAMB- liposomal amphotericin B.



Appendix Figure. Amplified fragment length polymorphism analysis showing fingerprints of common species of genus *Rhizopus*. The range of fragment lengths was between 100–480 bp, as denoted on the scale bar (top).